

# INCIDENTAL FINDINGS

## The Latest Management Recommendations

Click on the hyperlinks below:



### CT or MRI Abdomen/Pelvis:

[Adrenal Lesions](#)

[Pancreatic Cystic Lesions](#)

[Renal Lesions](#)

[Liver Lesions, no risk of HCC](#)

[Liver Lesions, risk of HCC \(LI-RADS\)](#)

[Splenic Lesions](#)

[Lymph Node Findings](#)

[Adnexal Lesions](#)

[Gallbladder and Biliary Lesions](#) \*new\*

### Ultrasound:

[Cystic Adnexal Lesions](#)

[Other Adnexal Lesions](#)

[Thyroid Nodules](#)

### Chest:

[Solid Pulmonary Nodules](#)

[Subsolid Pulmonary Nodules](#) \*new\*

### Vascular:

[Abdominal Aortic or Iliac Aneurysms](#)

[Penetrating Aortic Ulcers](#)

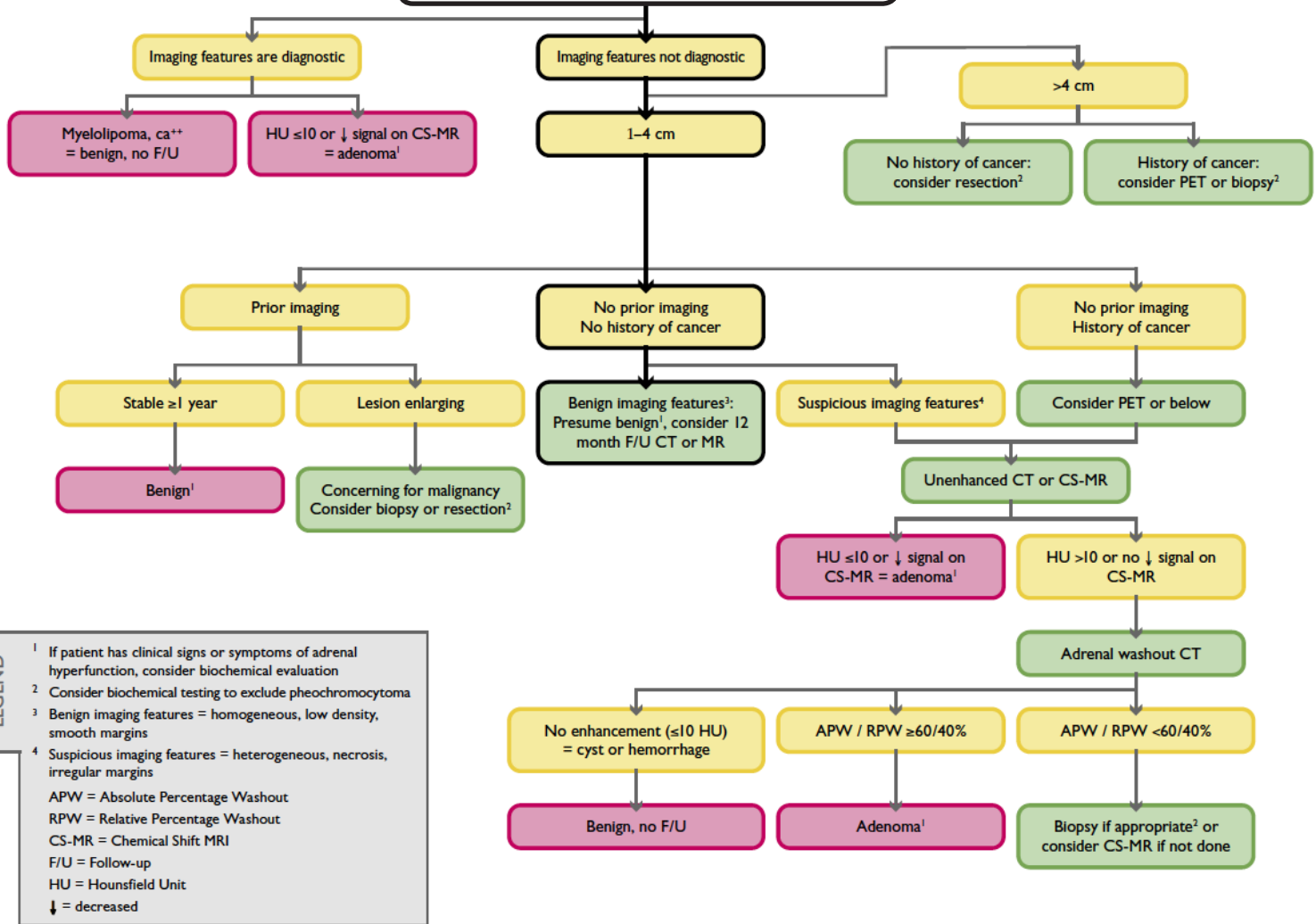
[Splenic or Renal Aneurysms](#)

[Other Abdominal Vascular Findings](#)

**Notes:** This resource is intended to be a readily available, continuously updated document for both residents and attendings to regularly refer to when making recommendations and management decisions for common incidental findings. The goal of this resource is to decrease variability in the way we manage incidental findings by implementing the best and most recent research and expert opinion. The ACR White Paper guidelines (and non-ACR guidelines herein) are not to be confused with the ACR Practice Guidelines and Technical Standards, do not represent official ACR policy, and should not represent the legal standard of care. Please share your feedback ([logan.dance@rochestergeneral.org](mailto:logan.dance@rochestergeneral.org)) and suggestions.



# Incidental Adrenal Mass ≥ 1 cm detected on CT or MR



Source: [White Paper: Managing Incidental Findings on Abdominal CT, JACR, October 2011](#)

## Relevant Links:

[Washout Calculator](#)

[Caoili et al: CT Characterization of Adrenal Masses, Radiology, 2002](#)

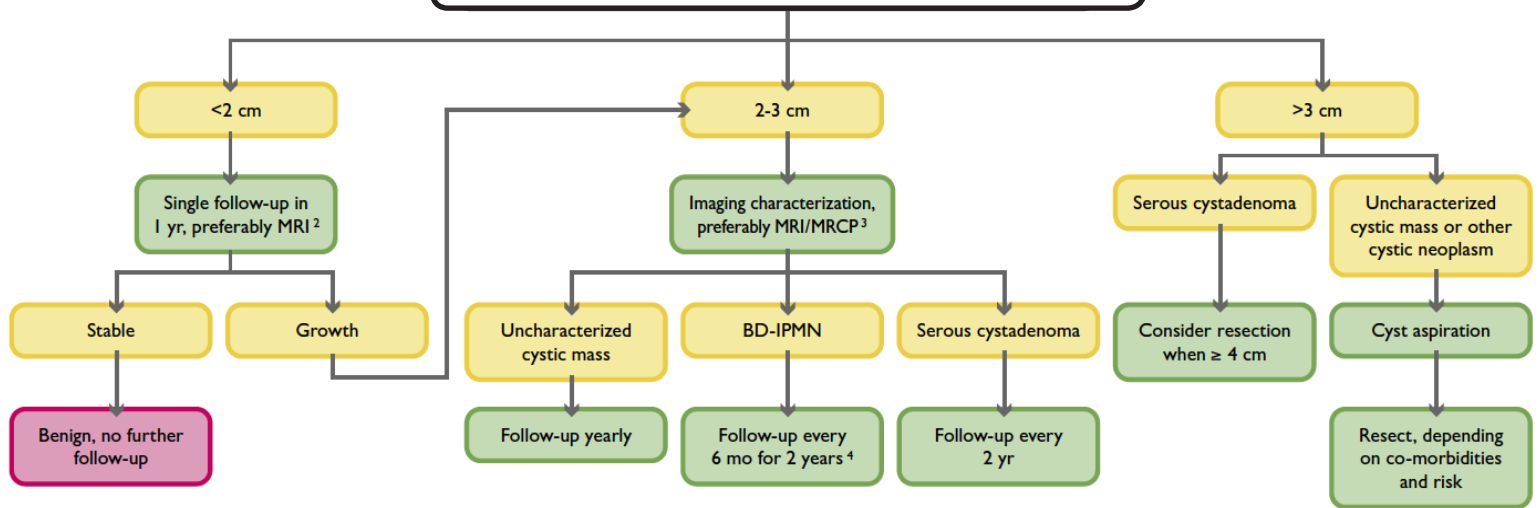
[ACR Appropriateness Criteria for Incidental Adrenal Nodule, 2006](#)

[Song et al: Prevalence of Adrenal Disease in 1049 Consecutive Adrenal Masses, AJR, 2008](#)

Of 1049 masses, 100% were benign in patients with no suspicion of malignancy.

## Incidental Cystic Pancreatic Mass

In an asymptomatic<sup>1</sup> patient, detected on CT, MRI (w/ or w/o contrast) or US.



### LEGEND

- 1 Signs and symptoms include hyperamylasemia, recent onset diabetes, severe epigastric pain, weight loss, steatorrhea or jaundice.
- 2 Consider decreasing interval if younger, omitting with limited life expectancy. Recommend limited T2-weighted MRI for routine follow-ups.
- 3 Recommend pancreas-dedicated MRI with MRCP.
- 4 If no growth after 2 years, follow yearly. If growth OR suspicious features develop, consider resection.
- 5 BD-IPMN = branch duct intraductal papillary mucinous neoplasm.

Source: [White Paper: Managing Incidental Findings on Abdominal CT, JACR, October 2011](#)

### Some Relevant Links:

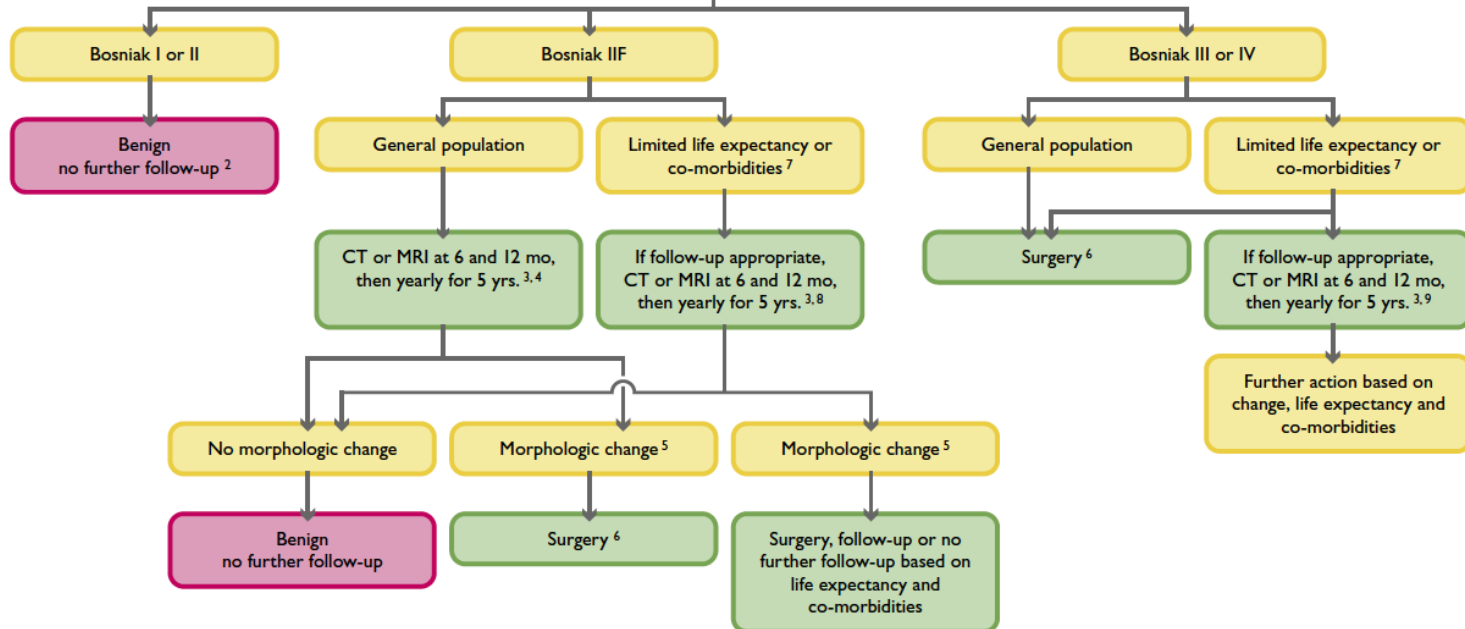
[Ip et. al., Focal Cystic Pancreatic Lesions: Variation in Management Recomm., Radiology, April 2011](#)

2.2% of CT's and 15.9% of MR's detect focal cystic pancreatic lesions.

[Sahani et. al., Pancreatic Cysts 3 cm or Smaller, Radiology, Mar. 2006](#)

87% of cysts <3cm were benign (75 of 86), 97% of unilocular cysts (35 of 36) were benign.

# Incidental Cystic Renal Mass detected on CT



## LEGEND

1 These recommendations are to be followed only if non-neoplastic causes of a renal mass (e.g., infections) have been excluded; see Ref. 48 for details. The recommendations are offered as general guidance and do not necessarily apply to all patients. See Table 1 for detailed description of Bosniak Classification.

2 When a mass smaller than 1 cm has the appearance of a simple cyst, further work-up is not likely to yield useful information.

3 Interval and duration of observation may be varied (e.g., longer intervals may be chosen if the mass is unchanged; longer duration may be chosen for greater assurance).

4 In selected patients (e.g., young), early surgical intervention may be considered, particularly if a minimally invasive approach (e.g., laparoscopic partial nephrectomy) can be utilized.

5 Morphologic change refers to change in feature characteristics, such as number of septations or their thickness. Growth should be noted, but by itself does not indicate malignancy.

6 Surgical options include open or laparoscopic nephrectomy and partial nephrectomy; each provides a tissue diagnosis. Open, laparoscopic, and percutaneous ablation may be considered where available, but biopsy would be needed to achieve a tissue diagnosis. Long-term (5- or 10-year) results of ablation are not yet known.

7 Limited life expectancy and co-morbidities that increase the risk of treatment.

8 Cystic masses 1.5 cm or smaller that are not clearly simple cysts or that cannot be characterized completely may not require further evaluation in patients with co-morbidities and in patients with limited life expectancy.

9 Percutaneous biopsy of Bosniak Category III masses may be considered, but may not be diagnostic.

## Management of Incidental Solid Renal Masses:

**1. General Population:** If less than 1 cm, these masses may be observed until they are 1 cm or larger (i.e. CT or MR at 3-6 mo then 12 mo). Lesions larger than 1 cm should be surgically removed, however, hyperattenuating homogeneously enhancing masses less than 3 cm may warrant further characterization with MRI and/or biopsy as these may be angiomyolipomas with minimal fat.

**2. Limited Life Expectancy and Comorbidities:** If less than 1 cm, these masses may be observed until they are 1.5 cm or larger (i.e. CT or MR at 3-6 mo then 12 mo). Lesions 1-3 cm may be followed or surgically removed, however, hyperattenuating homogeneously enhancing masses less than 3 cm may warrant further characterization with MRI and/or biopsy as these may be angiomyolipomas with minimal fat. Lesions larger than 3 cm may be followed or surgically removed.

**Source: White Paper: Managing Incidental Findings on Abdominal CT, JACR, Oct. 2011**

## Bosniak Criteria:

**Category I:** Hairline-thin wall; no septa, calcifications, or solid components; water attenuation; no enhancement.

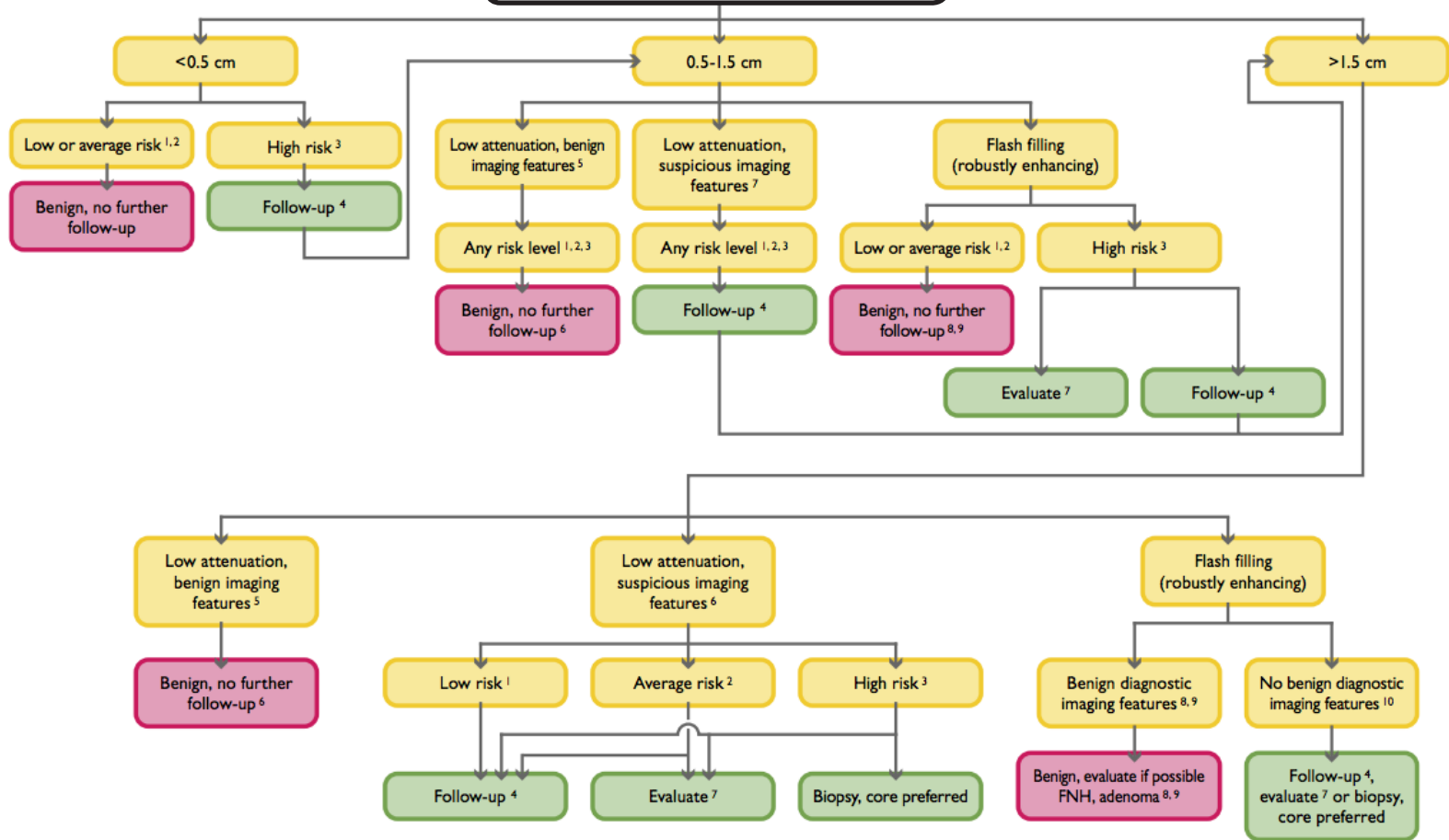
**Category II:** Few hairline-thin septa with or without perceived (not measurable) enhancement; fine calcification or short segment of slightly thickened calcification in the wall or septa; homogeneously high-attenuating masses ( $\leq 3$  cm) that are sharply marginated and do not enhance.

**Category IIF:** Multiple hairline-thin septa with or without perceived (not measurable) enhancement, minimal smooth thickening of wall or septa that may show perceived (not measurable) enhancement, calcification may be thick and nodular but no measurable enhancement present; no enhancing soft tissue components; intrarenal nonenhancing high-attenuation renal masses ( $> 3$  cm).

**Category III:** Thickened irregular or smooth walls or septa, with measurable enhancement.

**Category IV:** Criteria of category III, but also containing enhancing soft tissue components adjacent to or separate from the wall or septa.

## Incidental Liver Mass detected on CT



### Legend:

1. Low risk individuals: Young patient ( $\leq 40$  years old), with no known malignancy, hepatic dysfunction, hepatic malignant risk factors, or symptoms attributable to the liver.

2. Average risk individuals: Patient  $>40$  years old, with no known malignancy, hepatic dysfunction, abnormal liver function tests or hepatic malignant risk factors or symptoms attributable to the liver.

3. High risk individuals: Known primary malignancy with a propensity to metastasize to the liver, cirrhosis, and/or other hepatic risk factors. Hepatic risk factors include hepatitis, chronic active hepatitis, sclerosing cholangitis, primary biliary cirrhosis, hemochromatosis, hemosiderosis, oral contraceptive use, anabolic steroid use.

4. Follow-up CT or MRI in 6 months. May need more frequent follow-up in some situations, such as a cirrhotic patient who is a liver transplant candidate.

5. Benign imaging features: Typical hemangioma (see below), sharply marginated, homogeneous low attenuation (up to about 20 HU), no enhancement. May have sharp, but irregular margins.

6. Benign low attenuation masses: Cyst, hemangioma, hamartoma, Von Meyenberg complex (bile duct hamartomas).

7. Suspicious imaging features: Ill-defined margins, enhancement (more than about 20 HU), heterogeneous, enlargement. To evaluate, prefer multiphasic MRI.

8. Hemangioma features: Nodular discontinuous peripheral enhancement with progressive enlargement of enhancing foci on subsequent phases. Nodule isodense with vessels, not parenchyma.

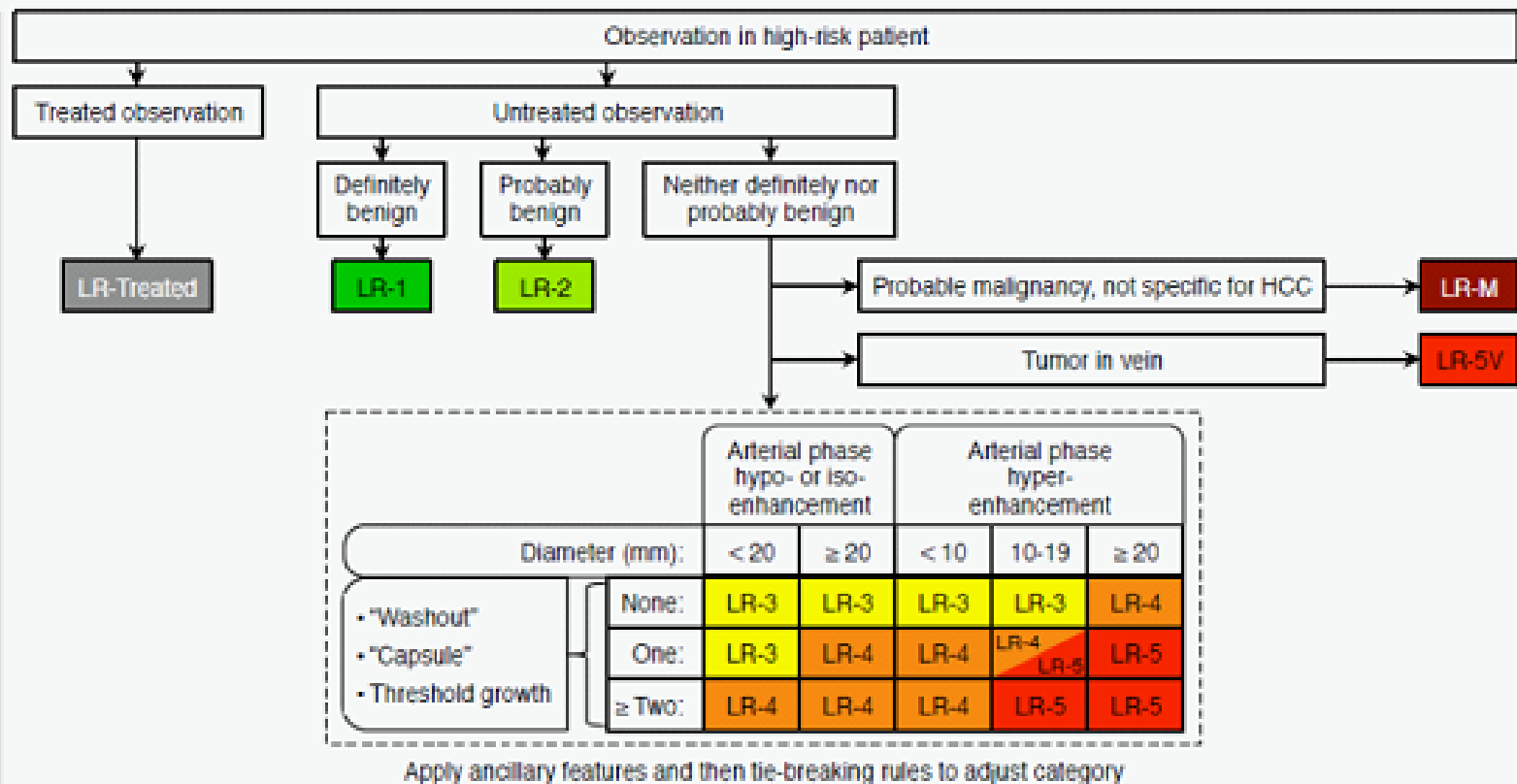
9. Small robustly enhancing lesion in average risk, young patient: hemangioma, focal nodular hyperplasia (FNH), transient hepatic attenuation difference (THAD) flow artifact, and in average risk, older patient: hemangioma, THAD flow artifact. Other possible diagnoses: adenoma, arterio-venous malformation (AVM), nodular regenerative hyperplasia. Differentiation of FNH from adenoma important especially if larger than 4 cm and subcapsular.

10. Hepatocellular or common metastatic enhancing malignancy: islet cell, neuroendocrine, carcinoid, renal cell carcinoma, melanoma, choriocarcinoma, sarcoma, breast, some pancreatic lesions.

# LI-RADS Criteria

For management of liver lesions in patients with cirrhosis or who are at risk for HCC.

ALGORITHM



Observations in this cell are categorized LR-4 except as follows:

- LR-5g, if there is ≥ 50% diameter increase in ≤ 6 months. These observations are equivalent to OPTN 5A-g.
- LR-5us, if there is both "washout" and visibility as discrete nodules at antecedent surveillance ultrasound, per AASLD HCC criteria.

## Categories:

### LR-1: Definitely benign

100% certainty that the lesion is benign.

### LR-2: Probably benign

High probability that the lesion is benign.

### LR-3: Intermediate probability of being HCC

Lesion does not meet criteria for other LI-RADS categories and is not a non-HCC malignancy.

Management varies.

### LR-4: Probably HCC

High probability but not 100%. Close follow-up, additional imaging, biopsy, or treatment may be appropriate. Doesn't contribute to radiologic T-staging unless multiple findings.

### LR-5: Definitely HCC

100% certainty. Treatment without biopsy is appropriate. Contributes to radiologic T-staging.

## Source:

This algorithm is the homepage of the [ACR LI-RADS](#)

[Manual](#) (click to view) which is an interconnected PDF

that acts like a webpage. Click on each of the categories

to view their formal definitions. Similar to the BI-RADS

manual, there are examples of each imaging feature as well

as each benign and malignant entity. Once you become

familiar with the manual, the above algorithm can help you

remember the key criteria.

**Facts:** HCC is the 3rd leading cause of cancer mortality worldwide and its incidence is increasing. 90% of primary liver cancer is HCC. Imaging surveillance for those at risk of HCC is a widely-accepted practice. A unique and challenging feature of hepatocellular carcinoma is its highly variable appearance, however, sometimes its imaging characteristics are so specific that treatment decisions can be made upon the assumption that the lesion represents HCC without actually first obtaining a biopsy (LR-5).



## Management of Adnexal Lesions

newly detected incidentally on US in asymptomatic\* nonpregnant females.

Cyst Size	Reproductive Age Female
$\leq 3$ cm †	No follow-up. Normal physiology. At your discretion, may not need to be described in the report.
$> 3$ to 5 cm	No follow-up. Describe in report and include “almost certainly benign”.
$> 5$ to 7 cm	Yearly follow-up. Describe in report and include “almost certainly benign”.
$> 7$ cm	Further evaluation with MR or surgery should be considered since these may be difficult to assess completely with US.

Cyst Size	Postmenopausal Female †
$\leq 1$ cm	No follow-up. Clinically inconsequential. At your discretion, may not need to be described in the report.
$> 1$ to 7 cm	Describe and include “almost certainly benign” and recommend yearly follow-up, at least initially, with US.
$> 7$ cm	Further imaging with MR or surgery.

\* These recommendations may be helpful in **symptomatic** women as well, but the clinical setting will often determine management in a manner beyond the scope of these recommendations.


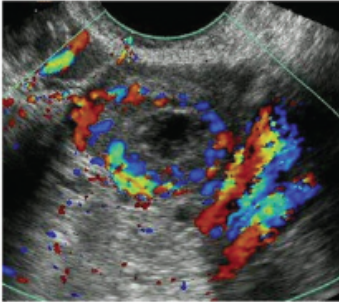
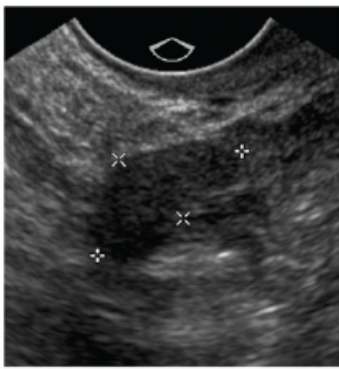

† **Size:** Use the maximum diameter.

• **Simple Cyst:** A simple cyst is round or oval, anechoic, smooth thin walls, posterior acoustic enhancement, no solid component or septation, and no internal flow. The entire cyst must be visualized. Assess all cysts with color/power Doppler. The rare cyst that turns out to be malignant is usually large ( $> 7$  cm) and the cyst wall was presumably incompletely imaged, with a missed small mural nodule. Over 99% of simple cysts up to 10cm in a patient of any age are benign, either non-neoplastic (physiologic, paraovarian, or paratubal) or benign neoplastic cysts (including serous and mucinous cystadenomas).

Follow-up recommendations for a **hemorrhagic cyst, endometrioma, dermoid, indeterminate lesion, and other lesions**, as well as simple cysts, are presented with example images in the tables on the following three pages.


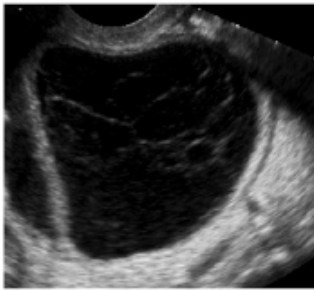
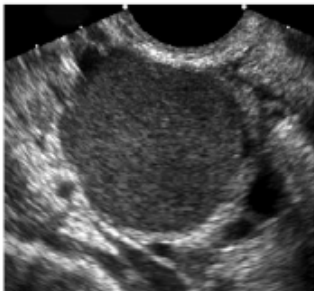


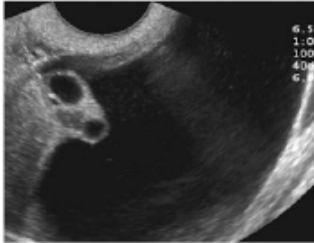
**Length of follow-up:** No consensus was reached regarding how long a lesion must be followed to demonstrate its stability. Cystic ovarian neoplasms generally grow very slowly.

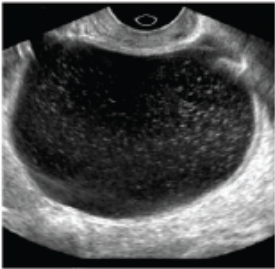
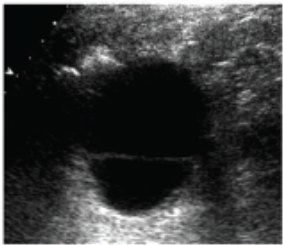

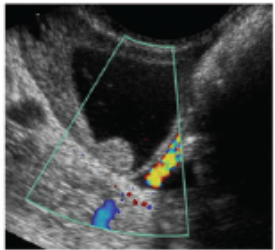

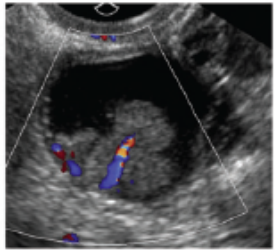
**Source:** Levine et. al. Management of Asymptomatic Ovarian and Other Adnexal Cysts Imaged at US, Society of Radiologists in Ultrasound Consensus Statement, Ultrasound Quarterly 2010;26:121-131.

Normal Appearance		Follow-up*	Comments
Normal ovary appearance: Reproductive age Follicles <ul style="list-style-type: none"> <li>• Thin and smooth walls</li> <li>• Round or oval</li> <li>• Anechoic</li> <li>• Size <math>\leq 3</math> cm</li> <li>• No blood flow</li> </ul>		Not needed	Developing follicles and dominant follicle $\leq 3$ cm are normal findings
Normal ovary appearance: Reproductive age Corpus luteum <ul style="list-style-type: none"> <li>• Diffusely thick wall</li> <li>• Peripheral blood flow</li> <li>• Size <math>\leq 3</math> cm</li> <li>• +/- internal echoes</li> <li>• +/- crenulated appearance</li> </ul>		Not needed	Corpus luteum $\leq 3$ cm is a normal finding
Normal ovary appearance: Postmenopausal <ul style="list-style-type: none"> <li>• Small</li> <li>• Homogenous</li> </ul>		Not needed	Normal postmenopausal ovary is atrophic without follicles
Clinically inconsequential: Postmenopausal Simple cyst $\leq 1$ cm <ul style="list-style-type: none"> <li>• Thin wall</li> <li>• Anechoic</li> <li>• No flow</li> </ul>		Not needed	Small simple cysts are common; cysts $\leq 1$ cm are considered clinically unimportant

Summary of recommendations for management of asymptomatic ovarian and other adnexal cysts. \* = Follow-up recommendations are for US, unless otherwise indicated. \*\* = Some practices may choose a threshold size slightly higher than 1 cm before recommending yearly follow-up. Practices may choose to decrease the frequency of follow-up once stability or decrease in size has been confirmed. (Figure continues.)



Cysts with benign characteristics		Follow-up*	Comments
<p>Simple cysts (includes ovarian and extraovarian cysts)</p> <ul style="list-style-type: none"> <li>• Round or oval</li> <li>• Anechoic</li> <li>• Smooth, thin walls</li> <li>• No solid component or septation</li> <li>• Posterior acoustic enhancement</li> <li>• No internal flow</li> </ul>		<p>Reproductive age:</p> <p>≤ 5 cm: Not needed</p> <p>&gt; 5 &amp; ≤ 7 cm: Yearly</p> <p>Postmenopausal (PM):</p> <p>&gt; 1 &amp; ≤ 7 cm: Yearly**</p> <p>Any age: &gt; 7 cm: Further imaging (e.g., MRI) or surgical evaluation</p>	<p>Simple cysts, regardless of age of patient, are almost certainly benign</p> <p>For cysts ≤ 3 cm in women of reproductive age, it is at discretion of interpreting physician whether to describe them in imaging report</p>
<p>Hemorrhagic cyst</p> <ul style="list-style-type: none"> <li>• Reticular pattern of internal echoes</li> <li>• +/- Solid appearing area with concave margins</li> <li>• No internal flow</li> </ul>		<p>Reproductive age:</p> <p>≤ 5 cm: Not needed</p> <p>&gt; 5 cm: 6-12 week follow-up to ensure resolution</p> <p>Early PM:</p> <p>Any size: Follow-up to ensure resolution</p> <p>Late PM: Consider surgical evaluation</p>	<p>Use Doppler to ensure no solid elements</p> <p>For cysts ≤ 3 cm in women of reproductive age, it is at the discretion of interpreting physician whether to describe them in imaging report</p>
<p>Endometrioma</p> <ul style="list-style-type: none"> <li>• Homogeneous low level internal echoes</li> <li>• No solid component</li> <li>• +/- Tiny echogenic foci in wall</li> </ul>		<p>Any age:</p> <p>Initial follow-up 6-12 weeks, then if not surgically removed, follow-up yearly</p>	
<p>Dermoid</p> <ul style="list-style-type: none"> <li>• Focal or diffuse hyperechoic component</li> <li>• Hyperechoic lines and dots</li> <li>• Area of acoustic shadowing</li> <li>• No internal flow</li> </ul>		<p>Any age:</p> <p>If not surgically removed, follow-up yearly to ensure stability</p>	
<p>Hydrosalpinx</p> <ul style="list-style-type: none"> <li>• Tubular shaped cystic mass</li> <li>• +/- Short round projections "beads on a string"</li> <li>• +/- Waist sign (i.e. indentations on opposite sides).</li> <li>• +/- Seen separate from the ovary</li> </ul>		<p>Any age:</p> <p>As clinically indicated</p>	
<p>Peritoneal inclusion cyst</p> <ul style="list-style-type: none"> <li>• Follow the contour of adjacent pelvic organs</li> <li>• Ovary at the edge of the mass or suspended within the mass</li> <li>• +/- Septations</li> </ul>		<p>Any age:</p> <p>As clinically indicated</p>	

Cysts with indeterminate, but probably benign, characteristics		Follow-up*	Comments
Findings suggestive of, but not classic for, hemorrhagic cyst, endometrioma or dermoid		Reproductive age: 6-12 week follow-up to ensure resolution. If the lesion is unchanged, then hemorrhagic cyst is unlikely, and continued follow-up with either ultrasound or MRI should then be considered. If these studies do not confirm an endometrioma or dermoid, then surgical evaluation should be considered.  Postmenopausal: Consider surgical evaluation	
Thin-walled cyst with single thin septation or focal calcification in the wall of a cyst		Follow-up based on size and menopausal status, same as simple cyst described above	
Multiple thin septations (< 3 mm)		Consider surgical evaluation	Multiple septations suggest a neoplasm, but if thin, the neoplasm is likely benign
Nodule (non-hyperechoic) without flow		Consider surgical evaluation or MRI	Solid nodule suggests neoplasm, but if no flow (and not echogenic as would be seen in a dermoid) this is likely a benign lesion such as a cystadenofibroma
Cysts with characteristics worrisome for malignancy		Follow-up*	Comments
Thick (> 3 mm) irregular septations		Any age: Consider surgical evaluation	
Nodule with blood flow		Any age: Consider surgical evaluation	

Source: Levine et. al. Management of Asymptomatic Ovarian and Other Adnexal Cysts Imaged at US, Society of Radiologists in Ultrasound Consensus Statement, Ultrasound Quarterly 2010;26:121-131.

## Management of Thyroid Nodules detected by ultrasound.

Ultrasound Feature	Recommendation
Microcalcifications	Strongly consider US-guided FNA if $\geq 1.0$ cm
Solid (or almost entirely solid) and/or coarse calcifications.	Strongly consider US-guided FNA if $\geq 1.5$ cm
Mixed solid and cystic, or almost entirely cystic with solid mural component.	Consider US-guided FNA if $\geq 2.0$ cm
Substantial growth since prior US exam.	Consider US-guided FNA
Almost entirely cystic and none of the above and no substantial growth (or no prior US)	US-guided FNA probably unnecessary
Multiple nodules	Consider US-guided FNA of one or more nodules, with selection prioritized on basis of criteria (in order listed) for solitary nodule

**Note:** Use largest measurement for size. FNA is likely unnecessary in a diffusely enlarged gland with multiple nodules of similar US appearance *without* intervening normal parenchyma. Presence of abnormal lymph nodes overrides US features of thyroid nodule(s) and should prompt US-guided FNA or biopsy of lymph node and/or ipsilateral nodule.

Ultrasound Features Associated with Thyroid Cancer	Sensitivity (%)	Specificity (%)	Positive Predictive Value (%)	Negative Predictive Value (%)
Microcalcifications	26 - 59	86 - 95	24 - 71	42 - 94
Hypoechoic	27 - 87	43 - 94	11 - 68	74 - 94
Irregular margins or no halo	17 - 78	39 - 85	9 - 60	39 - 98
Solid	69 - 75	53 - 56	16 - 27	88 - 92
Intranodule vascularity	54 - 74	79 - 81	24 - 42	86 - 97
More tall than wide	33	93	67	75

**Note:** Combining these factors improves the positive predictive value of US. For example, a predominantly solid nodule with microcalcifications has a 31.6% likelihood of being cancer, as compared to a predominantly cystic nodule with no calcification, which has a 1.0% likelihood of being cancer.

**Source:** [Frates et. al. Management of Thyroid Nodules Detected at Ultrasound, SRU Consensus Conference Statement. Radiology 2005;237:794-800 and Ultrasound Quarterly 2006;22:231-240.](#)

## Management of Pulmonary Nodules

newly detected incidentally at nonscreening CT in persons 35 or older.

Nodule Size*	Low-Risk Patient †	High-Risk Patient ‡
≤ 4 mm	No follow-up needed §	Follow-up CT at 12 months; if unchanged, no further follow-up
> 4 to 6 mm	Follow-up CT at 12 months; if unchanged, no further follow-up	Initial follow-up CT at 6–12 mo then at 18–24 mo if no change
> 6 to 8mm	Initial follow-up CT at 6–12 mo then at 18–24 mo if no change	Initial follow-up CT at 3–6 mo then at 9–12 and 24 mo if no change
> 8 mm	Follow-up CT at around 3, 9, and 24 mo, dynamic contrast-enhanced CT, PET, and/or biopsy	Same as for low-risk patient

**NOTE: Obtain 1 mm slices if the characteristics of the nodule are unclear. If the nodule is not solid or only partially solid, use the recommendations for subsolid pulmonary nodules on [the next page](#).**

**\* Size:**

Use average of length and width.

**† Low risk is defined as:**

Minimal or absent history of smoking or other known risk factors.

**‡ High risk is defined as one or more of the following:**

- ≥ 20 pack-year history of smoking, or equivalent second-hand exposure.
- Personal history of cancer or family history of lung cancer.
- Occupational exposure (asbestos, beryllium, silica, uranium, radon).
- Chronic interstitial/fibrotic lung disease.

**§ Low risk patient with ≤ 4 mm nodule:**

The risk of malignancy in this category (1%) is substantially less than that in a baseline CT scan of an asymptomatic smoker.

**Young Patients:** Primary lung cancer is rare in persons under 35 years of age (1% of all cases), and the risks from radiation exposure are greater than in the older population. Therefore, unless there is a known primary cancer, multiple follow-up CT studies for small incidentally detected nodules should be avoided in young patients. In such cases, a single low-dose follow-up CT scan in 6–12 months should be considered.

**Caution:**

1. Fever: In certain clinical settings, such as a patient presenting with neutropenic fever, the presence of a nodule may indicate active infection, and short-term imaging follow-up or intervention may be appropriate.
2. Cancer: Guidelines may not apply for individuals with known or suspected malignant disease.

**Source: [Guidelines for Management of Small Pulmonary Nodules Detected on CT Scans: A Statement from the Fleischner Society. Radiology 2005; 237:395-400.](#)**



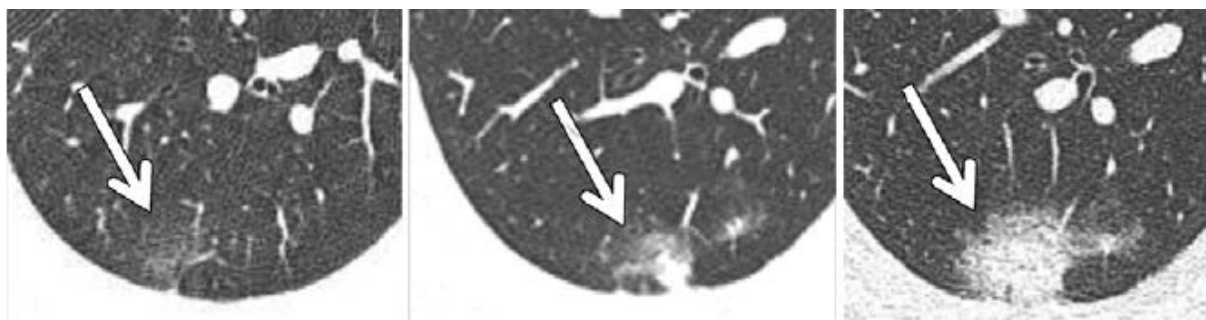
# Subsolid Pulmonary Nodules

## Fleischner Society Recommendations for Subsolid Nodules Found on CT

*The development of a standardized approach to the interpretation and management of subsolid nodules remains critically important given that peripheral adenocarcinomas represent the most common type of lung cancer, with evidence of increasing frequency.*

Nodule Type	Management Recommendations	Additional Remarks
Solitary pure GGN $\leq 5$ mm	No CT follow-up required.	Obtain contiguous 1-mm thin-sections to confirm that the nodule is truly a pure GGN.
Solitary pure GGN $> 5$ mm	3-month follow-up CT to confirm persistence, then yearly CT for a minimum of 3 years.	PET/CT is of limited value, potentially misleading, and therefore not recommended.
Solitary part-solid nodules	3-month follow-up CT to confirm persistence. If persistent with solid component $< 5$ mm, then yearly CT for a minimum of 3 years. If persistent with solid component $\geq 5$ mm, then biopsy/surgery.	Consider PET/CT for part-solid nodules $> 10$ mm.
Multiple pure GGNs $\leq 5$ mm	2-year and 4-year follow-up CT.	Consider alternate causes for multiple GGNs.
Multiple pure GGNs $> 5$ mm, without a dominant lesion	3-month follow-up CT to confirm persistence, then yearly CT for a minimum of 3 years.	PET/CT is of limited value, potentially misleading, and therefore not recommended.
Dominant nodule(s) with part-solid or solid component	3-month follow-up CT to confirm persistence. If persistent, biopsy or surgical resection is recommended, especially for lesions with $> 5$ mm solid component.	Consider lung-sparing surgery for patients with dominant lesion(s) suspicious for lung cancer.

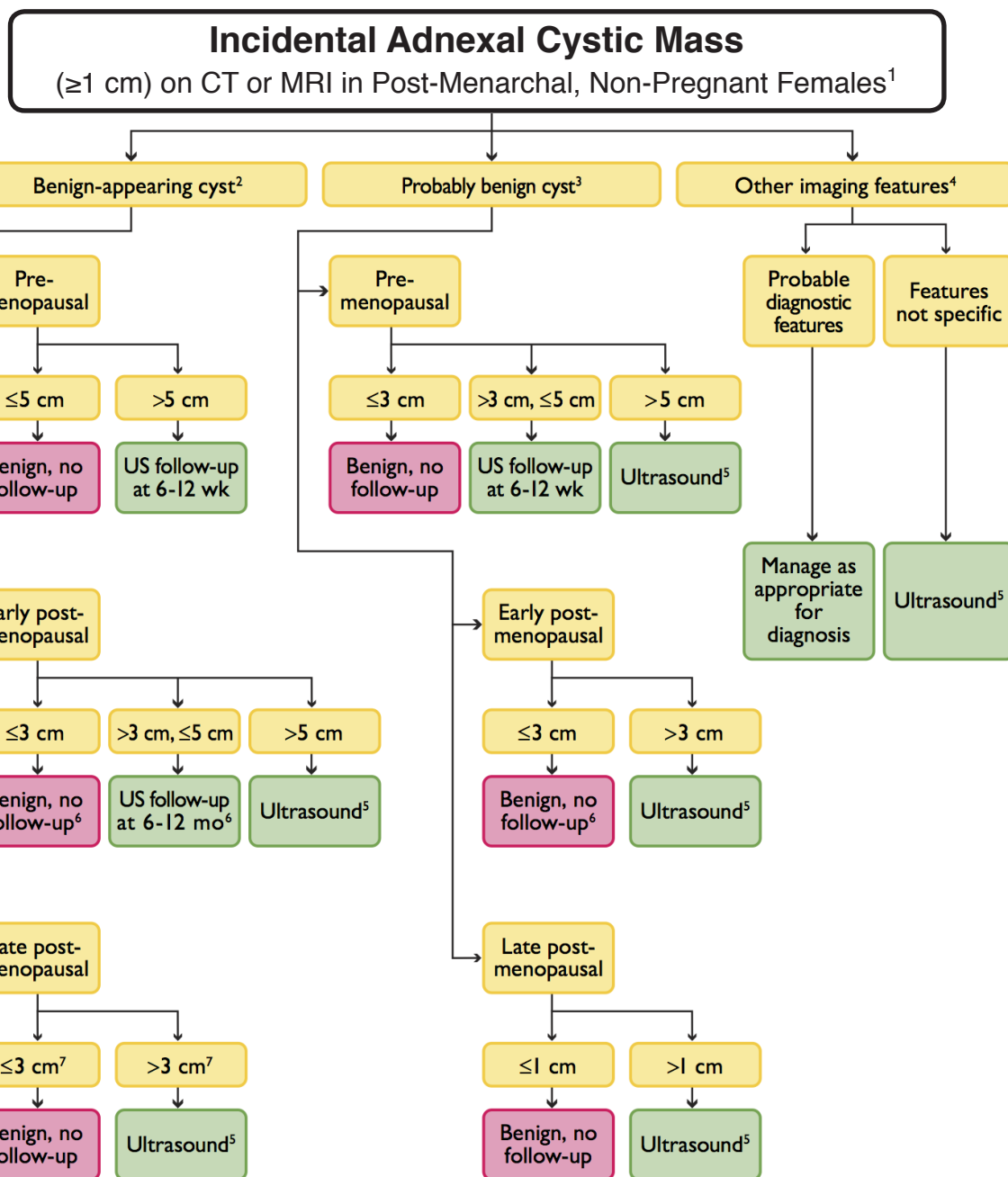
**Note:** These guidelines assume meticulous evaluation, optimally with contiguous thin sections (1 mm) reconstructed with narrow and/or mediastinal windows to evaluate the solid component and wide and/or lung windows to evaluate the nonsolid component of nodules, if indicated. When electronic calipers are used, bidimensional measurements of both the solid and ground-glass components of lesions should be obtained as necessary. With serial scans, always compare with the original baseline study to detect subtle indolent growth. The use of a consistent low-dose technique is recommended, especially in cases for which prolonged follow-up is recommended, particularly in younger patients. **See example:**



**Figure 4:** Value of initial short-term follow-up of malignant GGNs. Consecutive 1-mm-thick sections through right lower lobe section obtained at same anatomic level over a 6-month period (A, baseline; B, 3 months; C, 6 months) show rapid transformation of initial pure GGN (arrow in A) to a predominantly part-solid lesion (arrow in B and C), which subsequently proved to be mucinous adenocarcinoma.

**Source:** Naidich et al. Recommendations for the Management of Subsolid Pulmonary Nodules Detected at CT: A Statement from the Fleischner Society. Radiology, January 2013.





**1. Exclusions:** (a) normal findings, including hypodense ovary, crenulated enhancing wall of corpus luteum, asymmetric ovary (within 95% confidence interval for size) with normal shape; (b) unimportant findings, including calcifications without associated noncalcified mass; (c) previous characterization with ultrasound or MRI; and (d) documented stability in size and appearance for >2 years.

**2. Cyst:** should have all of the following features: (a) oval or round; (b) unilocular, with uniform fluid attenuation or signal (layering hemorrhage acceptable if premenopausal); (c) regular or imperceptible wall; (d) no solid area, mural nodule; and (e) <10 cm in maximum diameter.

**3.** Refers to an adnexal cyst that would otherwise meet the criteria for a benign-appearing cyst except for one or more of the following specific observations: (a) angulated margins, (b) not round or oval in shape, (c) a portion of the cyst is poorly imaged (eg, a portion of the cyst may be obscured by metal streak artifact on CT of the pelvis), and (d) the image has reduced signal-to-noise ratio, usually because of technical parameters or in some cases because the study was performed without intravenous contrast.

**4.** Features of masses in this category include (a) solid component, (b) mural nodule, (c) septations, (d) higher than fluid attenuation, and (e) layering hemorrhage if postmenopausal.

**5.** This indicates that ultrasound should be performed promptly for further evaluation, rather than in follow-up.

**6.** A benign-appearing cyst >5 cm with suspected internal hemorrhage in a patient aged >55 years, or within 5 years of menopause, should be followed in 6 to 12 weeks because hemorrhagic cysts in early postmenopause are possible, although rare.

**7.** May decrease threshold from 3 cm to lower values down to 1 cm to increase sensitivity for neoplasm.

## Abdominal Aortic Aneurysms

And ectatic abdominal aortas - recommended intervals for initial follow-up imaging

Aortic Diameter (cm)	Imaging Interval
2.5 - 2.9 cm	5 years (defined as ectatic)
3.0 - 3.4 cm	3 years
3.5 - 3.9 cm	2 years
4.0 - 4.4 cm	1 year
4.5 - 4.9 cm	6 months - also consider surgical or endovascular referral.
5.0 - 5.5 cm	3-6 months - also consider surgical or endovascular referral.

**Note:** An abdominal aorta  $\geq 1.5$  times the normal diameter or  $\geq 3.0$  cm or is defined as aneurysmal. For abdominal aortic diameters  $< 2.5$  cm, follow-up is generally thought to be unnecessary. Because the rupture of smaller abdominal aortic aneurysms is less likely, we recommend longer intervals between follow-up examinations. Follow-up intervals may vary depending on comorbidities and the growth rate of the aneurysm.

## Iliac Artery Aneurysms

Recommended intervals for initial follow-up imaging of common/internal/external iliac artery aneurysms

Aneurysm Diameter (cm)	Imaging Interval
$< 3.0$ cm	No explicit recommendation is made*
3.0 - 3.5 cm	6-month follow-up cross-sectional imaging
$> 3.5$ cm	Close follow-up or expeditious treatment

\*The white paper says, "Aneurysms that are  $< 3.0$  cm in diameter tend to be asymptomatic, rarely rupture, and expand slowly" and no recommendation is made. Simply describe the finding.

**Note:** Iliac artery aneurysm is defined as a diameter  $> 1.5$  times normal, or  $\geq 2.5$  cm in diameter.

## Penetrating Aortic Ulcers

Recommendations for follow-up imaging in asymptomatic patients

**Annual follow-up is recommended when asymptomatic, and more frequently if symptoms arise, with consideration of surgical/endovascular intervention.**

**Note:** Lack of symptoms does not necessarily imply stability. Studies have shown that the natural history of penetrating aortic ulcers (PAU) is variable and unpredictable. A PAU (which represents disruption of atherosclerotic plaque with penetration of luminal blood for variable distances into or through the aortic wall) may progress to an intramural hematoma, focal dissection, or pseudoaneurysm/rupture, or it may completely resolve.

**Source:** [White Paper: Managing Incidental Findings on Abdominal/Pelvic CT and MRI, Part 2: Vascular Findings, JACR, October 2013](#)

## Splenic Artery Aneurysms

### Recommended intervals for initial follow-up imaging

Aneurysm Diameter (cm)	Imaging Interval
< 2.0 cm	Yearly follow-up is recommended*
≥ 2.0 cm	Consider endovascular treatment

\*Clinical risk factors for rupture should be carefully assessed (such as attributable symptoms, a woman of child-bearing years, and cirrhosis, especially when associated with alpha-1 antitrypsin deficiency).

**Note:** Aneurysms showing rapid increase in size should be treated. Surveillance intervals greater than 1 year may be reasonable in patients with comorbidities and/or limited life expectancy.

## Renal Artery Aneurysms

### Recommended intervals for initial follow-up imaging

Aneurysm Diameter (cm)	Imaging Interval
1.0 - 1.5 cm	1-2 year follow-up imaging
> 1.5 to 2.0 cm	Consider surgical or endovascular treatment

Note: Consider the alternate diagnosis of a pseudoaneurysm due to trauma. Evaluate for evidence of fibromuscular dysplasia, particularly in younger women. The decision to treat a renal artery aneurysm should be based on factors including patient age, gender, presence of hypertension, and aneurysm location and size.

Vascular recommendations continued on next page...

## Other Abdominal Vascular Findings

**Pancreaticoduodenal aneurysms** are felt to be at higher risk for rupture, and some authors recommend that all of these aneurysms undergo surgical or endovascular treatment regardless of size. If a decision is made to observe rather than treat, repeat scanning at annual intervals is recommended.

Treatment is generally recommended for **aneurysms >2 cm in diameter**, possibly with a smaller threshold for nonatherosclerotic aneurysms. For **hepatic aneurysms**, Abbas et al established that multiplicity and nonatherosclerotic origin were linked to increased rupture rate.

Researchers have found that **isolated visceral arterial dissections** (typically the SMA) can be followed rather than treated promptly when asymptomatic.

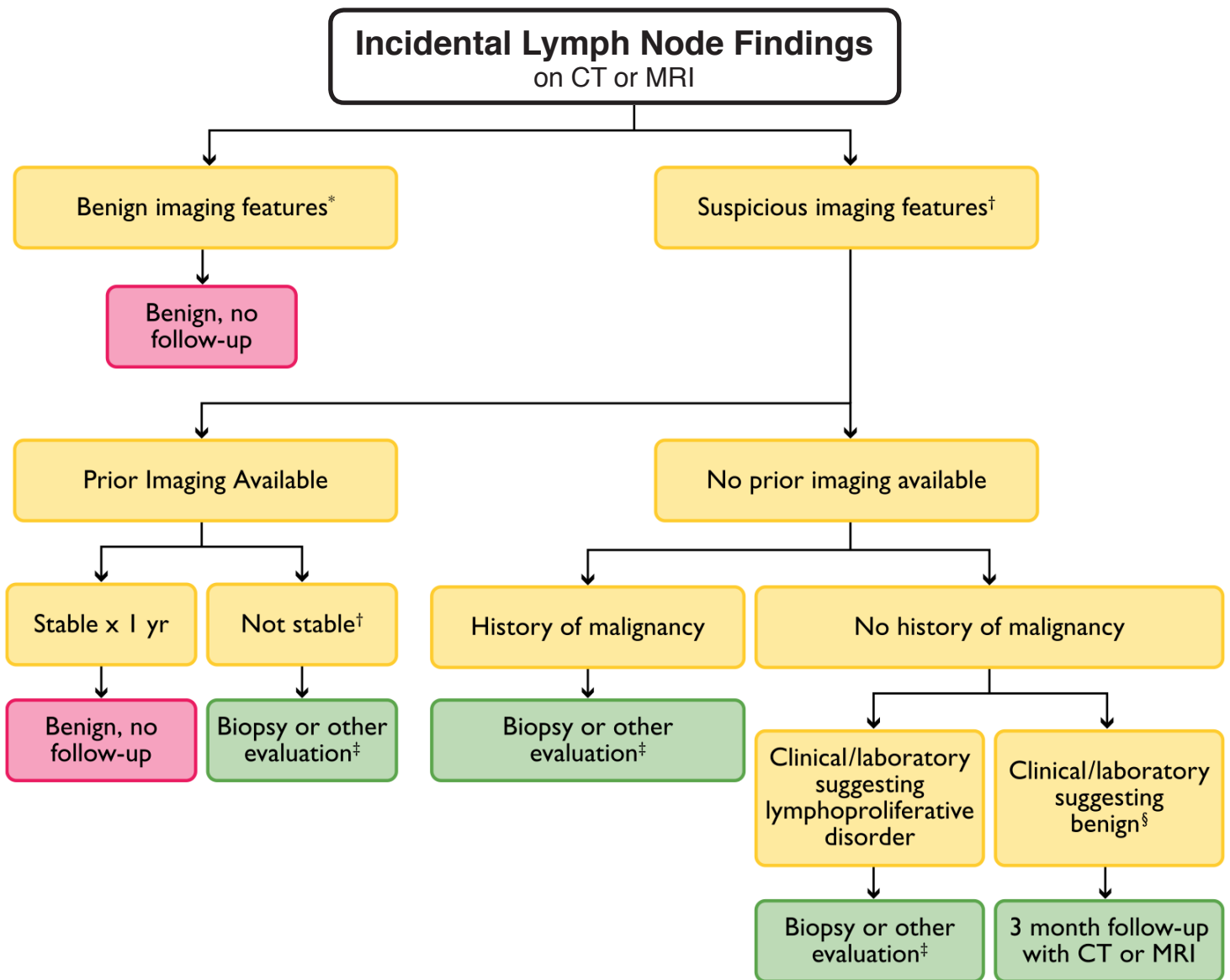
The **arcuate ligament** can occasionally compress the celiac axis origin; this is demonstrable on cross-sectional imaging performed at end-expiration. When noted incidentally in a patient without relevant symptoms, no further action is necessary.

**Atherosclerotic stenosis** commonly affects the celiac, SMA, and IMA. As long as this remains well compensated by collateral vessels and is not symptomatic with postprandial abdominal pain or weight loss, no further evaluation or follow-up is recommended.

The prevalence of **abominal venous thrombosis** on CT was 1.74% in a series of 2619 patients. How to further evaluate venous thrombosis depends on location and the local availability and expertise for particular techniques.

Although incompetence of the ovarian and draining pelvic veins (and resultant venous reflux) are considered the main cause of **pelvic congestion syndrome**, dilated pelvic veins are often seen incidentally in asymptomatic multiparous women. No further imaging or intervention is recommended in asymptomatic women with incidentally discovered dilated pelvic veins.

Both cadaveric and retrospective CT studies from asymptomatic patients suggest that compression of the left common iliac vein by the anteriorly crossing right common iliac artery (an anatomic variant known as **May-Thurner or ilio caval compression syndrome**) is present in approximately 25% of the population, indicating that most patients with compression are not symptomatic, and follow-up is not necessary unless the patient develops unilateral symptoms of leg swelling or thrombosis. Similarly, compression of the left renal vein between the aorta and superior mesenteric artery with localized varices, known as **nutcracker syndrome**, is an occasional asymptomatic incidental finding.



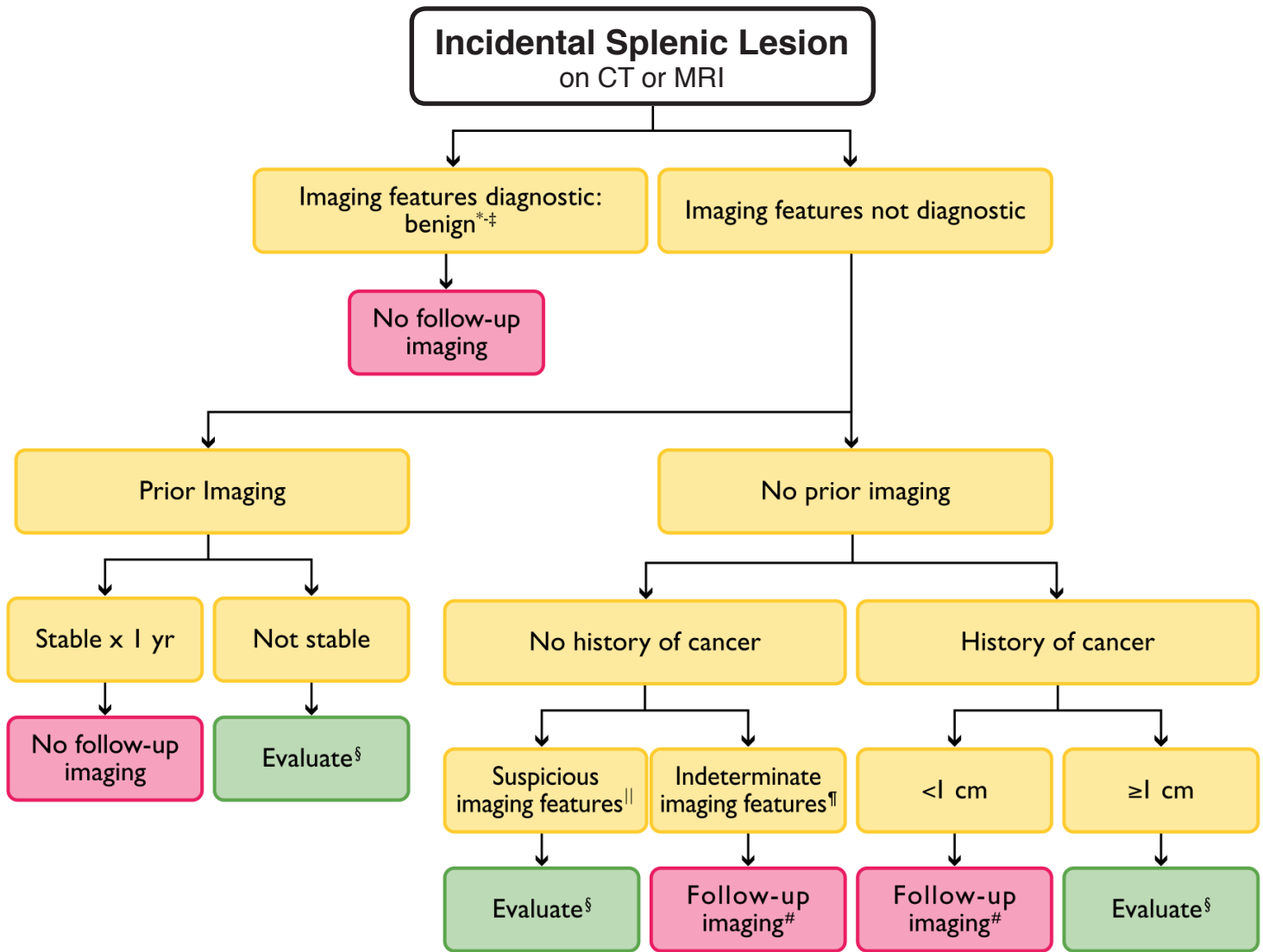
\* **Benign Features:** normal short-axis diameter (<1cm in retroperitoneum), normal architecture (elongated, fatty hilum), normal enhancement, normal node number.

† **Suspicious Features:** enlarged short-axis diameter ( $\geq 1$  cm in retroperitoneum), architectural distortion (round, indistinct hilum), enhancement (necrosis/hypervascular), increased number (cluster of  $\geq 3$  lymph nodes in a single nodal station or cluster of  $\geq 2$  lymph nodes in  $\geq 2$  regions).

‡ **Non-neoplastic Disease:** e.g. infection, inflammation, connective tissue disorders.

§ **Other Evaluation:** PET/CT, MIBG, endoscopic ultrasound.





\* **Cyst:** imperceptible wall, near-water attenuation (<10 HU), no enhancement.

\* **Hemangioma:** discontinuous, peripheral, progressively centripetal enhancement (these findings are less common in the spleen compared to the liver).

‡ **Benign features:** homogeneous low attenuation (<20 HU), no enhancement, smooth margins.

¶ **Indeterminate features:** heterogeneous, intermediate attenuation (>20 HU), enhancement, smooth margins.

|| **Suspicious features:** heterogeneous, enhancement, irregular margins, necrosis, splenic parenchymal or vascular invasion, substantial enlargement.

# **Follow-up:** MRI in 6-12 months.

§ **Evaluate:** PET vs. MRI vs. biopsy.

# Incidental Gallbladder and Bile Duct Findings

## Summary of Diagnosis and Management in Asymptomatic Patients evaluated by CT or MRI

Finding	Finding/Diagnosis	Action
Gallstones, no mass	Gallstones	If symptomatic, ultrasound
Gallbladder wall calcification, no mass	Focal or diffuse (porcelain gallbladder)	No follow-up recommended; if followed, use post-contrast CT
Dense gallbladder contents (20-100 HU)	Sludge, excreted contrast, hemorrhage, gallstones	No evaluation or follow-up recommended specifically for this finding
Diffuse gallbladder wall thickening > 3mm, no mass	Hepatitis, CHF, liver disease, pancreatitis, hypoproteinemia	No evaluation or follow-up recommended specifically for this finding
Focal gallbladder wall thickening or mass	Polyp, gallbladder cancer, cholesterosis, adenomyomatosis, xanthogranulomatous cholecystitis	Evaluation and follow-up depends on mass size, other clinical factors; ultrasound may show specific features for adenomyomatosis (i.e. "comet-tail" artifact)
Gallbladder polyp ≤ 6 mm	Benign polyp	No evaluation or follow-up recommended
Gallbladder polyp 7-9 mm	Benign polyp, adenoma, or small cancer	Follow yearly with ultrasound; surgical consult if polyp grows
Gallbladder polyp ≥ 10 mm, mass	Benign polyp, adenoma, or small cancer	Surgical consult
Pericholecystic fluid	Gallbladder perforation, other collection	Individual assessment
Distended gallbladder (> 4cm transverse, > 9cm long)	Fasting, obstruction	If asymptomatic, no evaluation
Ductal dilation > 6 mm, or > 10 mm if gallbladder absent	Obstruction, post-cholecystectomy	If lab results normal, no evaluation; if abnormal, ERCP, EUS, or MRCP as appropriate.

### Notes:

**1. Porcelain Gallbladder:** Large retrospective studies have shown that the prevalence of malignancy in resected porcelain gallbladders is 5-7% compared to 0.6 - 0.8% in the general population. Incidence of new cancer in a porcelain gallbladder is likely to be < 1% per year (inferred from available data); only a small fraction of this would likely be detected and treated differently if yearly follow-up were done. Therefore, the committee generally does not recommend follow-up.

**2. Diffuse gallbladder wall thickening:** In the absence of one of the above-mentioned secondary causes, a primary cause should be excluded by clinical history. If the thickening is uniform or nearly so, the risk for an underlying malignancy is negligible.

**3. Polyps:** Evidence for their management is inconclusive and based on ultrasound; the authors infer that this data is also applicable to CT and MRI. One study of 346 patients with gallbladder polyps found no malignancies and only one polyp 7-9 mm in size and two polyps > 10mm. Another study of 467 patients found that only 6.6% of polyps grew, and 3.7% were malignant or had malignant potential, including benign adenomatous and dysplastic potential. Only 0.7% were frankly malignant. The authors recommended follow-up for polyps 5-10 mm in size.

**4. Biliary duct dilatation:** Defined as > 6 mm in a patient < 60 years of age with the gallbladder present, or a common bile duct > 10 mm with the gallbladder absent. Because biliary dilatation is often chronic and asymptomatic, liver function tests (alkaline phosphatase, bilirubin) can help assess the importance of this finding. If there is suspicion of a biliary tract mass, MRCP may be performed. However, if the suspected mass is in the lower third of the common bile duct, endoscopic ultrasound (EUS) or ERCP-guided FNA may be preferred as the first option.

**Source:** [White Paper: Managing Incidental Findings on Abdominal/Pelvic CT and MRI, Part 4: Gallbladder and Biliary Findings, JACR, December 2013](#)